



## Sensorimotor tongue representation in individuals with unilateral upper limb amelia

Marion Funk<sup>a</sup>, Kai Lutz<sup>b</sup>, Sabina Hotz-Boendermaker<sup>c</sup>, Malgorzata Roos<sup>d</sup>, Paul Summers<sup>e</sup>, Peter Brugger<sup>a</sup>, Marie-Claude Hepp-Reymond<sup>f</sup>, Spyros S. Kollias<sup>e,\*</sup>

<sup>a</sup> Department of Neurology, University Hospital Zurich, Switzerland

<sup>b</sup> Department of Neuropsychology, Institute for Psychology, University Zurich, Switzerland

<sup>c</sup> Spinal Cord Injury Centre, Balgrist University Hospital Zurich, Switzerland

<sup>d</sup> Department of Biostatistics, University Zurich, Switzerland

<sup>e</sup> Institute of Neuroradiology, University Hospital Zurich, Frauenklinikstrasse 26, CH-8091 Zurich, Switzerland

<sup>f</sup> Institute of Neuroinformatics, University and ETH Zurich, Switzerland

### ARTICLE INFO

#### Article history:

Received 7 March 2008

Revised 30 May 2008

Accepted 4 June 2008

Available online 19 June 2008

#### Keywords:

Amelia

fMRI

Lateralization

Sensorimotor representation

Tongue

### ABSTRACT

The purpose of the present study was to examine the impact of the congenital absence of one hand on cortical organization of the sensorimotor cortex (S1/M1). We investigated the tongue representation in S1/M1 in nine participants with normally developed limbs, comprising the control group, and in eight persons with a congenitally completely missing hand (i.e. unilateral hand amelia). All participants were examined by fMRI while performing horizontal tongue movements. The significantly activated clusters covering S1/M1 in both hemispheres were analyzed with respect to the number and intensity of activated voxels, as well as the location of the activation. In the right-handed control group, the number of activated voxels was significantly higher in the left as compared to the right hemisphere demonstrating a clear left hemispheric motor dominance for horizontal tongue movements. In the amelic individuals, no such hemispheric lateralization effect was observed. The neural activation pattern underlying tongue movement, however, was enlarged and displaced in the hemisphere contralateral to the missing limb when compared to the respective motor non-dominant, right hemisphere of the control group participants. The present findings suggest that congenital absence of one hand leads to an appreciably altered topological organization of S1/M1 consisting of an enlargement of the tongue representation and a shift towards the “hand” area which, however, had never received any input from a hand.

© 2008 Elsevier Inc. All rights reserved.

### Introduction

The impact of the congenital absence of a hand (i.e. hand amelia) on organization of the sensorimotor cortex (S1/M1) may provide insight into the patterns of induced reorganization following injury to the brain, spine or hand itself. As a cortical neighbor to the stereotypical hand areas, the tongue representation is a good candidate for exploring the organizational differences arising in amelic individuals. A potential alteration in the cortical organization of amelic individuals is the aim of the present work.

Investigations into voluntary motor performance of tongue, lip, mouth, jaw and eyes are scarce. For fMRI, this is mainly due to artifacts associated with movement (Marquart et al., 2000) and to perturbations in the homogeneity of the magnetic field (Yetkin et al., 1996). This is unfortunate, considering the

importance of the human tongue in daily activities such as manipulation of food, swallowing, and chewing, and most important speaking.

Tongue movements, as investigated here, are preferable to lip movements because they have a larger representation in the S1/M1 than the lip (Hesselmann et al., 2004), and tongue movements with closed mouth are less prone to inducing fMRI artifacts. Moreover, it is well established that tongue movements are bilaterally represented in the inferior aspect of the homunculus, close to the lateral fissure (Penfield and Boldrey, 1937). A few attempts have been undertaken so far to locate the cortical tongue representation using neuroimaging techniques. Corfield et al. (1999) identified S1/M1, supplementary motor cortex, operculum, insula, thalamus, cerebellum, and medulla as being activated during tongue contraction. Others have established that the neural representation of motor tongue activity is distinct from the cortical representation of adjacent anatomical structures associated with swallowing and lip movements (Hesselmann et al., 2004; Martin et al., 2004).

\* Corresponding author. Fax: +41 44 255 45 04.

E-mail address: [kollias@usz.ch](mailto:kollias@usz.ch) (S.S. Kollias).

The potential for lateralized dominance in the cortical tongue representation remains unclear and is a subject of ongoing discussion. Wildgruber et al. (1996) reported strong bilateral activation during vertical tongue movements in the inferior primary motor cortex (M1), without any statistically significant lateralization. In contrast, an asymmetrical tongue representation in S1/M1 regarding the size of activation was observed during the performance of horizontal (Hesselmann et al., 2004), as well as vertical movements (Lotze et al., 2000; Martin et al., 2004), albeit not always with satisfactory statistical significance. In a recent study, Shinagawa et al. (2003) found that in right-handed individuals with an evident chewing-side preference (left-sided or right-sided placement of gum for first chew), tongue movements activated S1/M1 significantly more in the hemisphere contralateral to the preferred chewing side.

The tongue representation also shows both training and post-traumatic induced plastic changes that may last from a few minutes to permanent stage. Shinagawa et al. (2004) have reported transient plasticity of the S1/M1 tongue representation following bilateral gum chewing resulting in a balanced tongue representation despite the previously evident lateralization. Other recent studies have revealed that learning a novel tongue movement induces specific and reversible plasticity in S1/M1 representation in the range of minutes up to 1 week (Svensson et al., 2003, 2006). Long-term plasticity of the S1/M1 representation of orofacial structures has been examined primarily in the context of cortical reorganization in traumatic amputees and in spinal cord injured individuals (Karl et al., 2001; Lotze et al., 2001; Curt et al., 2002).

The relationship between use-dependent reorganization and inborn, malformation-induced altered organization of cortical representation has been illustrated in individuals with different degrees of upper extremity dysmelia due to thalidomide embryopathy, where shrinkage of the somatosensory (S1) hand area was not proportional to the number of missing fingers (Stoeckel et al., 2005). The relationship between the shrinkage of the hand area and the enlargement of the neighboring cortical areas however, was not examined. In traumatic amputees, individuals suffering from phantom pain showed extensive reorganization of M1 and/or S1 by presenting a significant shift of the lip or mouth representation towards the adjacent deafferented hand area (Flor et al., 1998; and Montoya et al., 1998 for S1 reorganization; Karl et al., 2001; and Lotze et al., 2001 for S1/M1 reorganization). In contrast, investigation of the cortical representation of orofacial structures amongst individuals with unilateral hand amelia (i.e. the complete, congenital absence of a hand; as the hand is congenitally absent, we deliberately avoid using the term re-organization) has shown the absence of pronounced intrusion into the S1 “hand” area, which had never received afferent input from a hand (Flor et al., 1998; Montoya et al., 1998). This is comparable to traumatic amputees who have never experienced phantom sensations or phantom pain (e.g., Lotze et al., 2001). However, significant alteration to the organization of S1 has been reported for one subject with bilateral arm amelia who did not report phantom sensations or phantom pain (Kamping et al., 2004).

From the limited studies performed to date in individuals with amelic or dysmelic limbs, it is difficult to draw clear conclusions regarding S1 and/or M1 organization. In this study, we have investigated the S1/M1 tongue representation

in normomelic, right-handed control participants (with normally developed limbs) and in eight individuals who lack afferent input to the hand area due to a congenitally missing hand. It was expected that the tongue representation in the amelic participants, who possibly did not develop a normal homunculus, would be enlarged and displaced towards the “hand” area. Additionally, we investigated whether hemispheric dominance of the tongue representation could be identified in the control group. Addressing the same question in the amelic group provides further the possibility to test whether potential inter-hemispheric differences in tongue representation would be influenced by an abnormal body representation.

## Materials and methods

### Participants



Eight unilaterally amelic subjects took part in this study along with nine right-handed, normomelic participants. All provided written informed consent for the participation in the experiment that was part of a study approved by the local ethics committee, and conducted in accordance with the Declaration of Helsinki.

For five of the amelic subjects (three males, two females, age: mean=32.0, SD=5.7 years) the left hand was congenitally absent, while in the remaining three (all males, age: mean=26.7, SD=4.5 years) the right hand was absent. In all cases, the hand was completely missing, with no evidence of partial or residual appendages. Table 1 gives the age and gender of the amelic individuals, side and extent of amelia, as well as a summary of the subject’s use (if any) of prosthesis. Only one member of the amelic group regularly used a myoelectric prosthesis, all the others used a cosmetic one. None of the amelic subjects had physical disabilities other than the missing hand, and none had ever experienced phantom pain or other phantom sensations. The cause of amelia was not known for any of the amelic subjects.

The age and education of the nine normomelic volunteers, who formed the control group, were well matched to the amelic group. This control group consisted of four females and five males (age: mean=30.0, SD=4.3 years), all strongly right-handed as measured by the Edinburgh Handedness Inventory (Oldfield, 1971).

Exclusion criteria for both the amelic and the normomelic participants included medical (except for the limb malformation) or mental illness, head injury, substance abuse, and use of any medication affecting the central nervous system.

**Table 1**  
List of amelic individuals with their individual characteristics

Side of amelia	Extent of amelia	Prosthesis	Age	Gender	
Right	Below elbow	Cosmetic	27	M	
Right	Only hand	No	31	M	
Right	Below elbow	Cosmetic	22	M	
Left	Below elbow	Cosmetic and myoelectric	37	M	
Left	Below elbow	Cosmetic	39	M	
Left	Below elbow	Cosmetic	28	F	
Left	Below elbow	Cosmetic	26	F	
Left	Below elbow	Myoelectric	30	M	

The amelic participants are listed in the same order in this table and in Table 3.

### Experimental procedure

All individuals performed a horizontal tongue movement task within a series of motor execution, mental imagery and observation tasks of hand, foot, and tongue movements. The amelic participants performed the tongue task once, whereas the control participants performed the same task twice within 2 weeks. The repetition of the tongue experiment in the control group was performed to test the reproducibility of the method in detecting and localizing the tongue representation in S1/M1.

The motor tongue task consisted of three 21-second periods of inactivity alternating with three 21-second periods of activity so that the duration of the total data collection was 126 s. The beginning and the end of each activation period were signaled with “go” and “stop” commands transmitted via headphones. During the active periods, participants moved the tip of their tongue horizontally from side to side (from one pair of incisors to the other) inside the mouth at a previously practiced, self-paced rate of approximately 1 Hz. During the period of inactivity, the tongue was kept in a resting position on the midline of the mouth. Prior to scanning session the task was demonstrated and practiced with the mouth open and subsequently closed under the supervision of the experimenter, to make certain that all individuals would correctly perform the task and avoid movements of the jaw and lips. None of the participants had difficulty in learning, performing, or repeating the task before the scan session. During the scanning session, participants kept their mouth and eyes closed at all times and were instructed to avoid eye movements.

### Data acquisition and analyses

Blood oxygenation level dependent (BOLD) fMRI was carried out on an 1.5-T MR scanner (Philips Intera, Best, The Netherlands) using a single-shot, gradient-echo, echo-planar imaging (GE-EPI) sequence (TR/TE 3000 ms/55 ms, flip angle 90°). For each of 42 time points, 30 contiguous, axial slices (3.4×3.4 mm in plane resolution with 5 mm slice thickness) covering the entire brain were acquired. The first two time points were discarded to eliminate T1 effects.

All fMRI data were processed and analyzed using statistical parametric mapping (SPM99, URL://[www.fil.ion.ucl.ac.uk/spm](http://www.fil.ion.ucl.ac.uk/spm)). All scans of each participant were realigned intra-individually to the first image of the session to correct for head movements. Since our primary dependent variable was the centres of gravity (COGs) of activated areas, some spatial resolution was sacrificed by smoothing with a 10 mm Gaussian kernel. Aside to increasing spatial dependency and thus power in a random field analysis, this has the effect of reducing differences in noise ratios between the x, y, and z dimension. The data were temporal band-pass filtered (high cut off 0.012 Hz, low cut off 0.25 Hz) and scaled to the global mean. A general linear model was set up for each individual and linear contrasts were applied according to Friston et al. (1995) to compare brain activation levels for the various task and rest conditions. Areas with statistically significant changes in signal intensity were determined by *t*-statistics on a voxel-by-voxel basis. Relying on cluster inference (Friston et al., 1994), clusters of neighboring voxels were identified as significantly activated if they passed a threshold of  $p < 0.05$  (corrected for multiple comparisons). The resulting statistical

parametric maps (SPMs) were used to derive further dependent variables.

Based on our own experience and other previous reports, horizontal tongue movements were expected to elicit bilateral activation clusters covering S1/M1 with the COG of each cluster being mainly located in the precentral gyrus (Alkadhi et al., 2002; Curt et al., 2002; Hesselmann et al., 2004). Motor and sensory responses cannot be differentiated with the specific task.

To quantify the size and intensity of activated areas in S1/M1, we determined the number of voxels (nVox) and the maximum *t*-value (tVox) within the most prominent (highest *t*-value) cluster including the inferior and lateral segment of the central sulcus. The data were not normalized prior to these analyses in order to preserve individual anatomical structures.

To compare the individual location of the activated clusters, a further analysis was performed on the data after anatomical normalization. Normalization was done according to the non-linear, non-label-based approach proposed by Ashburner and Friston (1999), which transforms individually oriented images into a comparable frame of reference and reduces inter-individual anatomical variability, so that remaining differences in cluster location may be attributed to shifted functional representation. In order to pool data of individuals with left hand amelia with (flipped) data of persons with right hand amelia, we used a reference space analogous to the MNI space (Evans et al., 1993), but transformed to a symmetrical image by calculating the mean image of the original MNI Template with its left–right flipped homologue. The COGs of the activated clusters in S1/M1 were determined for each individual separately as the vector sum of the coordinates of the activated voxels, weighted by their respective *t*-value and divided by the sum of *t*-values in the clusters. COGs were represented in [x,y,z] coordinates, which were assessed independently to derive measures of location in the medial–lateral, superior–inferior, and anterior–posterior axis.

### Quantitative and statistical analyses of activated regions

We tested the reproducibility of the fMRI method by applying the one sample *t*-test together with the corresponding 95% confidence interval (95% CI) to the differences between the measured parameters (i.e. number, intensity and location of the activated voxels of the cluster covering S1/M1) of the first and the second imaging sessions of the control subjects. As no significant differences in the relevant activation parameters were detected between the two sessions, only data from the first session were taken for further analysis. This kept the amount of data in the control and amelic groups comparable.

For the purposes of the remaining analyses, we defined the motor dominant hemisphere (hereafter referred to as “dominant hemisphere”) as the left hemisphere in the right-handed control participants and as the hemisphere controlling the single, normally developed hand in the amelic individuals. The hemisphere not so identified as dominant in each individual was taken to be the motor non-dominant hemisphere (hereafter “non-dominant hemisphere”). Testing was first performed to check for inter-hemispheric (dominant vs. non-dominant hemisphere) differences in activation size, intensity and location of the S1/M1 tongue representation in each group separately (Wilcoxon signed rank test). Then, the dominant and non-dominant hemispheres of the amelic

**Table 2**

Measured activation parameters in the control group: mean differences between the first and the second scanning sessions

	Difference between the first and the second sessions, mean value	<i>p</i> -value	95% CI lower	95% CI upper
Number of activated voxels				
Right hemisphere	18.00	0.47	-38.70	74.70
Left hemisphere	9.42	0.71	-50.96	69.81
Intensity of activated voxels, <i>t</i> -value				
Right hemisphere	-0.35	0.66	-2.25	1.55
Left hemisphere	-0.86	0.19	-2.30	0.58
Centre of gravity (COG)				
<i>x</i> right hemisphere	1.33	0.29	-1.5	4.18
<i>y</i> right hemisphere	-1.7	0.65	-10.62	7.14
<i>z</i> right hemisphere	-0.41	0.86	-5.89	5.08
<i>x</i> left hemisphere	-0.56	0.31	-0.69	1.80
<i>y</i> left hemisphere	1.01	0.11	-0.33	2.35
<i>z</i> left hemisphere	-3.51	0.27	-10.48	3.45

Listed are means with corresponding *p*-values and the range indicated by lower and upper 95% CI.

subjects were compared to those of the control participants (Mann–Whitney *U* test). Since the distribution of the dependent variables cannot be assumed to be symmetric in most cases and due to the relatively small number of subjects in the investigated groups, non-parametric analyses were conducted for the above-mentioned statistics. The corresponding 95% CI to all calculated differences was computed.

#### Technical considerations of the present study

A slice thickness of 5 mm was used, as the participants performed the tongue task within a series of other motor tasks, which required scanning of the whole brain in a reasonable amount of time. A higher spatial resolution focused on the S1/M1 area may have been favorable for the

present study. However, with regard to the duration of the scanning session and the compliance of the patients, a reduction of the scanning time seemed preferable. The COG of an activated area seemed suitable, since it is insensitive to the amount of locally independent activation maxima within a certain area. Also, the measures used to assess laterality of activation volumes are relative measures, insensitive to the absolute extend of activated clusters. Though not applied in the present study, a most sophisticated control of the tongue performance could have been achieved by training the performance with a visual feedback consisting of electromyographic activities of the orofacial muscles (see Shinagawa et al., 2003).

## Results

### Test of reproducibility of the fMRI tongue representation in normomelic subjects

The reproducibility of the anatomical localization of the tongue representation was assessed by calculating the differences in number, intensity and COG coordinates of the activated voxels between the first and the second performance of the tongue motor task by the controls. The mean differences for each of these variables, together with corresponding *p*-values and 95% CIs are listed in Table 2. No statistically significant differences in activation were found between the two imaging sessions for any of the quantities of interest.

### Quantitative estimation of the activated areas

Illustrating the reliability of the tongue movement paradigm, all participants showed significantly activated clusters in bilateral S1/M1 during horizontal tongue movements. The individual data of the amelic and the control participants are listed in Table 3.

**Table 3**

Quantitative analysis of the volumes, maximum *t*-values, and centres of gravity coordinates of the motor tongue representations in amelic and control participants

Side of amelia	nVox DH	tVox DH <i>t</i> -values	nVox nDH	tVox nDH <i>t</i> -values	COG DH			COG nDH		
					<i>x</i>	<i>y</i>	<i>z</i>	<i>x</i>	<i>y</i>	<i>z</i>
Right	71 (RH)	6,30	39 (LH)	6,45	57	-6	25	-37	-8	61
Right	358 (RH)	11,82	330 (LH)	11,56	58	-18	20	-54	-15	38
Right	351 (RH)	9,72	435 (LH)	8,36	57	-3	17	-46	-14	43
Left	115 (LH)	7,57	196 (RH)	8,01	-56	-2	29	51	-7	41
Left	288 (LH)	14,07	328 (RH)	13,79	-49	-6	32	50	-2	36
Left	174 (LH)	8,54	143 (RH)	9,60	-55	-6	34	57	-6	35
Left	68 (LH)	7,49	81 (RH)	7,76	-59	-3	17	58	-3	20
Left	123 (LH)	7,26	251 (RH)	9,20	-56	-7	33	52	-5	35
Mean	193.5	9,1	225.3	9,3	55.8 <sup>a</sup>	-6.3	25.8	50.8 <sup>a</sup>	-7.5	38.6
SD	121.3	2,6	139.9	2,3	3.0	5.0	7.1	6.7	4.7	11.3
No	48 (LH)	6,06	27 (RH)	5,84	-59	0	22	56	3	34
No	259 (LH)	9,41	274 (RH)	9,60	-57	1	28	61	7	25
No	39 (LH)	6,12	13 (RH)	5,69	-52	-5	22	57	-8	24
No	140 (LH)	10,72	74 (RH)	7,62	-56	-7	24	57	-4	26
No	215 (LH)	10,03	183 (RH)	11,08	-57	-11	35	58	-4	24
No	70 (LH)	6,26	9 (RH)	5,27	-58	-2	23	62	-5	17
No	121 (LH)	7,21	63 (RH)	6,71	-58	-4	27	60	2	26
No	53 (LH)	5,98	58 (RH)	8,46	-58	-5	19	59	-3	17
No	107 (LH)	6,39	73 (RH)	6,96	-58	-10	29	57	-13	34
Mean	116.9	7,6	86.0	7,5	57.0	-3.9	25.4	58.5	-2.7	25.2
SD	77.1	1,9	87.4	1,9	2.0	5.0	4.8	2.0	6.0	6.1

*nVox* and *tVox*: number and intensity of significantly activated voxels of the cluster covering S1/M1 in each individual subject's dominant and non-dominant hemispheres. COG: centre of gravity. RH: right hemisphere, LH: left hemisphere, DH: dominant hemisphere, nDH: non-dominant hemisphere. Individual data and means with standard deviations for amelic and control participants.

<sup>a</sup> For the mean COGs in the amelic group, the *x*-coordinates are given in absolute numbers.



The normomelic participants showed the expected bilateral activations in S1/M1 and the mean difference in extent of activation between the two hemispheres was 30.9 voxels, 95% CI (9.1, 52.6). Thus, significantly more voxels were activated in the dominant (i.e. left) as compared to the non-dominant (i.e. right) hemisphere (Wilcoxon  $Z=2.3$ ,  $p=0.02$ ). The intensity of the activated voxels did not differ between the two hemispheres (Wilcoxon  $Z=0.18$ ,  $p=0.86$ ).

The amelic individuals showed task-related activation in S1/M1 similar to those of the control participants, but without significant inter-hemispheric differences in number (Wilcoxon  $Z=1.2$ ,  $p=0.20$ ) or intensity (Wilcoxon  $Z=0.17$ ,  $p=0.85$ ) of activated voxels. This was also true when examining sub-groups (missing right hand, missing left hand) for which no significant inter-hemispheric differences were seen.

The mean value with corresponding 95% CI of the number of activated voxels in the amelic participants wearing cosmetic prosthesis was 218, 95% CI (78.9, 357.7) in the dominant hemisphere and 226, 95% CI (58.2, 393.7) in the non-dominant hemisphere. One of the amelic participants was using a myoelectric prosthesis, whereas all other ones had a cosmetic prosthesis. The number of activated voxels in the amelic individual with myoelectric prosthesis was 123 voxels in the dominant and 251 voxels in the non-dominant hemisphere, both of which are within the confidence interval of the amelic participants with cosmetic prosthesis. This individual was therefore included in the group statistics for amelic participants.

Comparisons between the amelic and control groups regarding the number and intensity of activated voxels in S1/M1 revealed no differences between the dominant hemispheres (Mann–Whitney  $Z=1.5$ ,  $p=0.12$  for number,  $Z=1.6$ ,  $p=0.10$  for intensity).

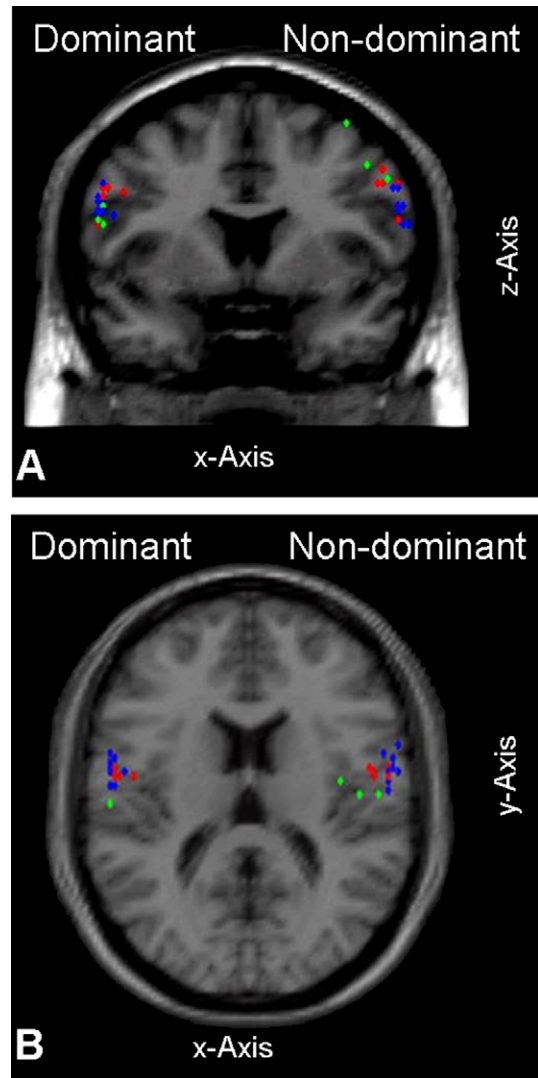
In contrast, the non-dominant hemisphere (i.e. the right hemisphere of the control participants, and the hemisphere contralateral to the absent hand in the amelic participants) had a higher number of activated voxels in the amelic group than in the control group (Mann–Whitney  $Z=2.3$ ,  $p=0.02$ ). The amelic group had a mean of 225 activated voxels, 95% CI (111, 339) and the control group of 86, 95% CI (18, 153) in the non-dominant hemisphere. No significant difference in intensity was found between the two groups (Mann–Whitney  $Z=1.7$ ,  $p=0.09$ ).

#### Location of the tongue representation in the control and amelic group

Fig. 1 displays the individual COGs (rounded to the nearest voxel centre) in S1/M1 for both hemispheres and all individuals. Table 3 lists the coordinates of each individual separately, as well as their means and standard deviations. The  $x$ -,  $y$ -, and  $z$ -coordinates of the COG in the dominant and the non-dominant hemispheres of the amelic subject with myoelectric prosthesis were within the confidence interval boundaries of the other amelic participants.

In the control group the COGs in S1/M1 did not differ significantly in the dominant and the non-dominant hemisphere. This is in agreement with tongue representation coordinates previously reported by our group (Alkadhi et al., 2002; Curt et al., 2002).

In contrast, in the amelic group, the COGs in S1/M1 of both hemispheres were significantly different for the  $z$ -coordinate (Wilcoxon  $Z=2.5$ ,  $p=0.01$ ) since the mean difference between



**Fig. 1.** Displayed are the locations of the individual COGs of tongue movement activations after normalization. *Green*: participants with a right hand amelia (data are flipped left-right to group COGs with respect to dominant and non-dominant hemisphere, as explained in the text). *Red*: participants with a left hand amelia. *Blue*: normomelic participants. A:  $x$ ,  $z$  coordinates projected onto a coronal section through the most anterior COG. B:  $x$ ,  $y$  coordinates projected onto a transverse section through the most inferior COG.

the dominant and non-dominant hemisphere was  $-13$ , 95% CI ( $-23.1$ ,  $-2.0$ ), indicating that the location of the tongue representation was more superior in the non-dominant hemisphere (contralateral to the missing limb) than in the dominant one. The inter-hemispheric comparison between the COGs in the two amelic subgroups (right or left missing hand) did not reveal any significant difference.

For the dominant hemisphere, the comparison of the COGs of activation in S1/M1 did not reveal any significant difference between control and amelic participants. In contrast, in the non-dominant hemisphere the COGs of the amelic subjects differed significantly in their  $x$ -coordinates (Mann–Whitney  $Z=-2.8$ ,  $p<0.01$ ) and  $z$ -coordinates (Mann–Whitney  $Z=-2.8$ ,  $p<0.01$ ). As shown in Table 3, the COGs in the amelic group were located significantly more medially (95% CI [45.2, 56.3]) and superiorly (95% CI [29.2, 47.9]) than those of the control group (95% CI [57.1, 60.1] for  $x$ ; and 95% CI [20.4, 30.0] for  $z$ ).

## Discussion

The main findings of the present investigation can be summarized as follows: (1) normomelic, right-handed individuals exhibit reproducible bilateral activation with a left hemispheric dominance for horizontal tongue movements with respect to the size of the activated cluster. (2) In this group, the locations of the activated clusters do not differ between the two hemispheres. (3) Amelic subjects do not show hemispheric differences in the size of activation. (4) The motor tongue representation in the non-dominant hemisphere of the amelic participants is significantly enlarged and displaced superiorly as compared to the corresponding, non-dominant hemisphere of the control participants. These results evidently indicate that the congenital absence of a hand leads to a significantly altered topological organization of S1/M1.

### *Hemispheric tongue dominance in normomelic participants*

The present study demonstrates left hemispheric dominance for tongue movements in normomelic, right-handed individuals, with a greater volume of activation in 78% of these participants. No inter-hemispheric difference was evident for the COG coordinates of the activated clusters. The inter-hemispheric asymmetry in activation volume and the symmetry in location of the activated clusters in S1/M1 were comparable in both first and second imaging sessions.

Differing hypotheses have been advanced regarding the basis of hemispheric lateralization of tongue motor function. [Martin et al. \(2004\)](#) suggested that the orofacial sensorimotor cortices within the left and the right hemisphere are functionally non-equivalent in that the left postcentral gyrus may be specialized for processing oral sensory input based on its phylogenetic specialization for oral language. Asymmetrical tongue representation could thus be tied to functional inter-hemispheric differences in language processing ([Picard and Olivier, 1983](#)). Lateralization may also reflect an asymmetry in the activity of the articulatory muscles despite of bilateral corticobulbar innervations, as suggested by [Szirtes and Vaughan \(1977\)](#).

The validity of these hypotheses is weakened by the conflicting reports as to the presence or absence of lateralization. Thus, while our results are consistent with previous studies reporting lateralization (based on activated cluster size) to the left hemisphere ([Hesselmann et al., 2004](#); [Martin et al., 2004](#)), other groups did not observe any significant inter-hemispheric differences and concluded that the motor tongue representation is symmetric, at least when the tongue movements were executed within a non-language related context ([Wildgruber et al., 1996](#); [Corfield et al., 1999](#); [Fesl et al., 2003](#)). Moreover, the symmetric inter-hemispheric location of tongue in our normomelic subjects reproduces the findings of a recent report ([Hesselmann et al., 2004](#)), yet contradicts other studies reporting asymmetrical COGs of activation ([Lotze et al., 2001](#); [Martin et al., 2004](#)).

The relationship between asymmetries in cortical tongue representation and hemispheric lateralization of language processing has not been addressed in the literature to date. Similarly, they are not quantitative studies on the degree of motor tongue lateralization and its relationship to handedness. Indirect conclusions have been drawn from studies on chewing-side preference ([Shinagawa et al., 2003, 2004](#); [Nissan](#)

[et al., 2004](#)), which showed that the preferred side of chewing could be a good indicator for behavioral tongue asymmetry and suggested the existence of a link between handedness, behavioral and neurofunctional tongue dominance.

Differences in tasks (i.e. horizontal tongue movements, tongue elevation, tongue contraction), statistical analysis of the data (lateralization was not statistically tested in some studies), and imaging parameters may be responsible for the above-mentioned divergent findings. Our task involved tongue movement in a distinctly non-language context and, although myographic monitoring was not available, it appeared to allow conformance by all subjects. The high reliability and reproducibility of the cortical tongue representation in our study favor the presence of an asymmetry.

### *Adapted topography in S1/M1 of amelic individuals*

In contrast to the strong lateralization of the motor tongue representation observed in the control participants, only 38% of the amelic individuals had a larger volume of activation in their dominant as opposed to their non-dominant hemisphere. Group analysis revealed that both volume and intensity of activation did not differ between the two hemispheres over the group of amelic participants and over the amelic subgroups (left and right hand missing). This finding leads us to the conclusion that amelic individuals do not show significant hemispheric lateralization for the S1/M1 tongue representation.

In addition to the non-lateralized S1/M1 tongue representation, a clear enlargement and superior shift of the COGs of activation clusters in S1/M1 of their non-dominant hemisphere was observed. This finding demonstrates that congenital absence of a limb is associated with alteration of the S1/M1 tongue representation in the hemisphere devoid of hand control. Specifically, it suggests that cortical organization adapts with enlargement and shift of the S1/M1 tongue area towards the presumptive “hand” area. A limitation of our study is that the relatively coarse resolution of the fMRI acquisition does not allow distinction between S1 and M1. Therefore, comparisons of our results with previous studies which investigated plastic changes in S1 organization in individuals with congenital limb atrophy and in traumatic amputees with and without phantom sensations ([Flor et al., 1998](#); [Montoya et al., 1998](#)) would be rather speculative.

Nevertheless, our findings strongly suggest that early changes in the development of the motor homunculus of amelic individuals occur even in the absence of phantom sensations in the respective limb. The results of our single amelic individual using a myoelectric prosthesis, as compared to the ones wearing a cosmetic one, also suggest that the use of such prosthesis does not prevent an adapted cortical organization in amelics, in contrast to the data in traumatic amputees by [Lotze et al. \(1999\)](#).

In summary, the present investigation provides evidence that the left hemispheric dominance for non-language related tongue movements, found in healthy right-handers, is abolished in amelic individuals. These findings indicate that the establishment of a motor tongue dominance in healthy controls is linked to the development of a normal homunculus and suggest that the sensorimotor cortex does not only react in a plastic manner to body part changes (e.g. limb amputation) during lifetime but also during development in the case of amelia.

## Acknowledgment

This work was supported by the Swiss National Science Foundation (grant no. 3100-67168.01).

## References

- Alkadhi, H., Crelier, G.R., Boendermaker, S.H., Golay, X., Hepp-Reymond, M.C., Kollias, S.S., 2002. Reproducibility of primary motor cortex somatotopy under controlled conditions. *Am. J. Neuroradiol.* 23, 1524–1532.
- Ashburner, J., Friston, K.J., 1999. Nonlinear spatial normalization using basis functions. *Hum. Brain Mapp.* 7, 254–266.
- Corfield, D.R., Murphy, K., Josephs, O., Fink, G.R., Frackowiak, R.S., Guz, A., Adams, L., Turner, R., 1999. Cortical and subcortical control of tongue movement in humans: a functional neuroimaging study using fMRI. *J. Appl. Physiol.* 86, 1468–1477.
- Curt, A., Alkadhi, H., Crelier, G.R., Boendermaker, S.H., Hepp-Reymond, M.C., Kollias, S.S., 2002. Changes of non-affected upper limb cortical representation in paraplegic patients as assessed by fMRI. *Brain* 125, 2567–2578.
- Evans, A.C., Collins, D.L., Mills, S.R., Brown, E.D., Kelly, R.L., Peters, T.M., 1993. 3D statistical neuroanatomical models from 305 MRI volumes. *Proc. IEEE-Nuclear Science Symposium and Medical Imaging* 1813–1817.
- Fesl, G., Moriggl, B., Schmid, U.D., Naidich, T.P., Herholz, K., Yousry, T.A., 2003. Inferior central sulcus: variations of anatomy and function on the example of the motor tongue area. *NeuroImage* 20, 601–610.
- Flor, H., Elbert, T., Muhlneckel, W., Pantev, C., Wienbruch, C., Taub, E., 1998. Cortical reorganization and phantom phenomena in congenital and traumatic upper-extremity amputees. *Exp. Brain Res.* 119, 205–212.
- Friston, K.J., Worsley, K.J., Frackowiak, R.S.J., Mazziotta, J.C., Evans, A.C., 1994. Assessing the significance of focal activations using their spatial extent. *Hum. Brain Mapp.* 1, 210–220.
- Friston, K.J., Holmes, A.P., Worsley, K.J., Poline, J.P., Frith, C.D., Frackowiak, R.S.J., 1995. Statistical parametric maps in functional imaging: A general linear approach. *Hum. Brain Mapp.* 2, 189–210.
- Hesselmann, V., Sorger, B., Lasek, K., Guntinas-Lichius, O., Krug, B., Sturm, V., Goebel, R., Lackner, K., 2004. Discriminating the cortical representation sites of tongue and lip movement by functional MRI. *Brain Topogr.* 16, 159–167.
- Kamping, S., Lutkenhoner, B., Knecht, S., 2004. Shifting of cortical somatosensory areas in a man with amelia. *Neuroreport* 15, 2365–2368.
- Karl, A., Birbaumer, N., Lutzenberger, W., Cohen, L.G., Flor, H., 2001. Reorganization of motor and somatosensory cortex in upper extremity amputees with phantom limb pain. *J. Neurosci.* 21, 3609–3618.
- Lotze, M., Grodd, W., Birbaumer, N., Erb, M., Huse, E., Flor, H., 1999. Does use of a myoelectric prosthesis prevent cortical reorganization and phantom limb pain? *Nat. Neurosci.* 2, 501–502.
- Lotze, M., Flor, H., Grodd, W., Larbig, W., Birbaumer, N., 2001. Phantom movements and pain. An fMRI study in upper limb amputees. *Brain* 124, 2268–2277.
- Lotze, M., Seggewies, G., Erb, M., Grodd, W., Birbaumer, N., 2000. The representation of articulation in the primary sensorimotor cortex. *Neuroreport* 11, 2985–2989.
- Martin, R.E., MacIntosh, B.J., Smith, R.C., Barr, A.M., Stevens, T.K., Gati, J.S., Menon, R.S., 2004. Cerebral areas processing swallowing and tongue movement are overlapping but distinct: a functional magnetic resonance imaging study. *J. Neurophysiol.* 92, 2428–2443.
- Marquart, M., Birn, R., Haughton, V., 2000. Single- and multiple-event paradigms for identification of motor cortex activation. *Am. J. Neuroradiol.* 21, 94–98.
- Montoya, P., Ritter, K., Huse, E., Larbig, W., Braun, C., Topfner, S., Lutzenberger, W., Grodd, W., Flor, H., Birbaumer, N., 1998. The cortical somatotopic map and phantom phenomena in subjects with congenital limb atrophy and traumatic amputees with phantom limb pain. *Eur. J. Neurosci.* 10, 1095–1102.
- Nissan, J., Gross, M.D., Shifman, A., Tzadok, L., Assif, D., 2004. Chewing side preference as a type of hemispheric laterality. *J. Oral. Rehabil.* 31, 412–416.
- Oldfield, R.C., 1971. The assessment and analysis of handedness: the Edinburgh Inventory. *Neuropsychologia* 9, 97–113.
- Picard, C., Olivier, A., 1983. Sensory cortical tongue representation in man. *J. Neurosurg.* 59, 781–789.
- Penfield, W., Boldrey, E., 1937. Somatic motor and sensory representation in the cerebral cortex as studied by electrical stimulation. *Brain* 60, 389–443.
- Shinagawa, H., Ono, T., Ishiwata, Y., Honda, E., Sasaki, T., Taira, M., Iriki, A., Kuroda, T., 2003. Hemispheric dominance of tongue control depends on the chewing-side preference. *J. Dent. Res.* 82, 278–283.
- Shinagawa, H., Ono, T., Honda, E., Sasaki, T., Taira, M., Iriki, A., Kuroda, T., Ohya, K., 2004. Chewing-side preference is involved in differential cortical activation patterns during tongue movements after bilateral gum-chewing: a functional magnetic resonance imaging study. *J. Dent. Res.* 83, 762–766.
- Stoeckel, M.C., Jorgens, S., Witte, O.W., Seitz, R.J., 2005. Reduced somatosensory hand representation in thalidomide-induced dysmelia as revealed by fMRI. *Eur. J. Neurosci.* 21, 556–562.
- Svensson, P., Romaniello, A., Arendt-Nielsen, L., Sessle, B.J., 2003. Plasticity in corticomotor control of the human tongue musculature induced by tongue-task training. *Exp. Brain Res.* 152, 42–51.
- Svensson, P., Romaniello, A., Wang, K., Arendt-Nielsen, L., Sessle, B.J., 2006. One hour of tongue-task training is associated with plasticity in corticomotor control of the human tongue musculature. *Exp. Brain Res.* 173, 165–173.
- Szirtes, J., Vaughan Jr, H.G., 1977. Characteristics of cranial and facial potentials associated with speech production. In: Desmedt, J.E. (Ed.), *Language and Hemispheric Specialization in Man: Cerebral Event-Related Potentials*. Progress in Clinical Neurophysiology, Vol. 3. S. Karger, Basel, pp. 112–116.
- Wildgruber, D., Ackermann, H., Klose, U., Kardatzki, B., Grodd, W., 1996. Functional lateralization of speech production at primary motor cortex: a fMRI study. *Neuroreport* 7, 2791–2795.
- Yetkin, F.Z., Haughton, V.M., Cox, R.W., Hyde, J., Birn, R.M., Wong, E.C., Probst, R., 1996. Effect of motion outside the field of view on functional MR. *Am. J. Neuroradiol.* 17, 1005–1009.